

Effect of titanium plate fixation on bone healing

Norain Binti Abdullah¹, Masaaki Nakai*¹, Yuki Kawamura², Ei Yamamoto², Mitsuo Niinomi^{3,4,5,6}

¹Faculty of Science and Engineering, Kindai University

²Faculty of Biology-Oriented Science and Technology, Kindai University

³Institute for Materials Research, Tohoku University

⁴Graduate School of Engineering, Osaka University

⁵Graduate School of Science and Technology, Meijo University

⁶Institute of Materials and Systems for Sustainability, Nagoya University

*Corresponding author: nakai@mech.kindai.ac.jp

Abstract

Bone formation which is a process before bone remodeling in fracture healing process, was investigated in this study by fixing metallic plate after an artificially created defect in a rabbit femur. Although a complete bone remodeling takes about 6 weeks, present study was conducted by observing the condition of the bone within 3 weeks of healing period. An artificial defect was made in a rabbit femur and Ti-6Al-4V ELI (Ti-64) fixation plate was fixed with two screws on both ends while a defect without fixation was set as the control. After 3 weeks, the femur bone was harvested and evaluated with scanning electron microscopy, Vickers hardness test, and X-ray diffraction analysis. Ti-64 fixation showed rapid bone formation but external callus remaining on the defect area and its surrounding bone area. This bone callus may be replaced with healed bone with the passage of time. On the other hand, control showed incomplete bone formation and bone callus formed in the area without the defect, including further regions from the defect area. This may be affected by irregular load transmission and instability around the bone defect area. We conclude that, Ti-64 fixation shows better bone formation and bone hardness than the control.

1. Introduction

Bone formation or ossification is process by which new bone is produced. This process begins about the third month of fetal life in humans and completed by late adolescence. Compact bone makes up roughly 80 percent of the skeleton and the other is cancellous bone which including parts of the skull, the shoulder blades and the end of the long bones. At birth, bone formation is incomplete but a process of bone resorption and deposition called bone remodeling produce mature bone.

Fractures in bones, traumatic or pathologic, are the most common orthopedic problems. In fracture healing process, bone repair and regeneration are important thus understanding of this process is needed in order to improve clinical treatment [1]. Fracture healing process mainly consists of the inflammatory response, soft callus formation, hard callus formation, initial bone union and then bone remodeling. There are mainly four stages of fracture healing process [2]. Fracture healing process is different between human and smaller animals which remodeling process in human takes about 4 months while in much smaller animals such as rabbit, only about 6 weeks [3,4]. Due to bone fracture, implant is needed to support the fracture for bone to heal.

Over the past years, metallic biomaterials such as stainless steels and Co-Cr alloys are widely being used. However, these metallic biomaterials have much greater Young's modulus as compared to natural bones. The Young's modulus of the most widely used stainless steel SUS316L and Co-Cr alloys are around 200 GPa and 200-300 GPa, respectively [5,6]. On the other hand, titanium alloys have been promising as orthopedics implants due to their excellent corrosion resistance and good biocompatibility [6,7,8]. Other than that, commercially used titanium alloys in biomedical applications, i.e., Ti-6Al-4V ELI has a lower Young's modulus of 110 GPa [5,6]. This low Young's modulus characteristics is important because it is being said that metallic biomaterials that has Young's modulus near to the bone has potential to prevent stress shielding which can leads to poor bone remodeling due to bone resorption [9,10,11]. Regardless of this phenomenon, only several studies described osseointegration during cortical and trabecular bone healing [3,4,12]. Moreover, we found that it is important to study fracture healing during the bone formation in order to have a better understanding of healing process.

Considering this situation, present study aimed to investigate the effect of fixation using metallic plate on bone formation during healing period of a fracture. This study reports the first 3 weeks of healing period, using rabbit model where the bone formation is observed and bone properties is evaluated including surrounding bone area noted that the total remodeling process of rabbit is 6 weeks [4].

2. Material and experiments

2.1 Sample preparation

Annealed Ti-6Al-4V ELI (Ti-64) alloy sheets with a thickness of 2.0 mm (VSMPO-AVISMA Corporation, Sverdlovsk, Russia) were used to prepare the fixation plate. The alloy sheets were cut into 25.0 mm x 5.0 mm size of fixation plate by electric discharge machining (EDM). The thickness of the implant plate were adjusted by lathe machine from 2.0 mm to 0.5 mm. Then, two holes were made on both ends of the fixation plate. After that, all samples were polished using SiC waterproof abrasive paper sheet from #80 to #800 grit. All samples were placed in acetone then cleaned using ultrasonic cleaning machine for 10 minutes and rinsed with water. Lastly, the samples were wiped and placed into a container.

2.2 Implantation in rabbit femurs

Adult female white rabbits of 3.0-4.0 kg in weight were kept with free access to food and water for 2 weeks before surgery. The rabbits were anesthetized with pentobarbital injection before surgery. The knee joint region was scrubbed with iodine and then cut open until femur was visible. An artificial defect of 5.0 mm length and 3.0 mm depth was made in the rabbit femur using a rectangular flat rasp. Then, drilling on the bone through the holes were done before fixing the screws. After that, fixation plate of Ti-64 alloy was fixed on the defect with two screws on the both ends. The surgery site was rinsed with penicillin solution to avoid infection. On the other hand, artificial defect with no fixation was set as control. All experimental procedures using rabbits were approved by the Animal Experiment Committee of Faculty of Biology-Oriented Science and Technology, Kindai University.

2.3 Histological observation

After survival periods of 3 weeks, the rabbits were sacrificed and femurs were euthanized. The femurs were placed in salt water before any further experiments and placed in the refrigerator. In order to conduct experiments, femurs were cut down with 5 mm in size from center of the defect and also area outside from the fixation plate for Ti-64 fixation and the same comparable area for control. All bone samples were rinsed with water. Then, the samples were embedded in resin and left for 4 to 5 hours until the resin harden. Polishing were done as described in previous studies [13,14]. After that, observation was carried out by scanning electron microscope equipped with energy dispersive X-ray spectroscopy (SEM/EDS).

2.4 Bone properties evaluation

2.4.1 Vickers hardness test

After observations were done, Vickers hardness test were carried out on bone samples. All indentations were performed under a controlled load with a maximum applied load of 0.5 N and a loading time of 10 s. Indentations were performed on existed bone and bone callus that formed after fixation (bone with holes structure). The test was done 40 times in existed bone and varied number of times on the bone callus. Lastly, the results obtained were calculated in average and plotted on a bar chart.

2.4.2 X-ray diffraction analysis

X-ray diffraction analysis was carried out using Bruker AXS D8 Discover X-ray diffraction analysis (XRD). Cu-K α radiation was generated at a tube voltage of 40 kV and a tube current of 40 mA, and the incident beam was focused onto a beam spot by collimeter with 800 μ m in diameter. A few point of test were conducted on each bone samples.

3. Results and discussion

3.1 Histological evaluation

SEM observation show the cross-sections of the bone on the defect area differ between Ti-64 fixation and control (Figs. 1,2). Regarding energy dispersive spectroscopy, we can see the composition of calcium which defined with grey color. Both bone callus and actual bone composed of calcium. However, we can see that the part with actual bone show much darker grey color than bone callus that show lighter grey color. During Ti-64 fixation, defect area already unseen but bone callus (external callus) were still present (Fig. 1a,d). Other than that, bone callus did not appeared on the opposite side of defect area (Fig. 1b,e). Even though bone formation of rabbit was said to be at least 4 weeks, in this study it was shown that rapid bone formation is achieved when using Ti-64 fixation [3]. On the other hand, control show incomplete bone formation on the defect area and bone callus is still present including on the opposite site of defect area (Fig. 2a,d,b,e). Not only delayed bone formation was observed, it also can be said that all around the defect area was affected when no fixation was done.

The observation of cross-section of bone were not only done on center but also on part which is far from the defect area. In Ti-64 fixation, bone callus did not appeared on area far from the defect area (Fig. 1c,f). This show that normal bone formation is achieved and no irregular callus is formed. In control, bone callus still appear on the area that are not related to defect including far away from the defect area (Fig. 2c,f). This condition is reversed from that of Ti-64 fixation which shows that with no fixation, bone callus formation is irregular and uncontrollable. This is because, in normal fracture healing process, bone callus was said to be normal which occurs between 2-3 weeks and become distinct and thus, bone union will be achieved at 4 weeks [15,16]. Other than that, bone callus usually formed solely on defect area. However, in this study it can be said that bone callus formation is abnormal since the bone callus formed beyond normal condition especially in control. From this study, it can be suggested that irregular bone callus formation was affected by non-uniform load transmission during healing period. Previous study stated that appearance of any visible callus indicates the instability of fracture site [2,11,15,17]. Hence, this study suggests that there was uniform load transmission along the bone during Ti-64 fixation but in control,

non-uniform load transmission happened thus provoke the irregular bone callus formation including the part that far away from defect area. Without fixation, mechanical stability cannot be achieved by the bone and resulted in abnormal fracture healing process [16]. As far we know, bone callus (external callus) is normally formed in defect area during primary bone formation stage then will disappear as time passes and formed rigid bone [2,18]. Therefore, this study needs to be prolonged to find out whether the bone callus will disappear as the theory said in order to confirm the advantage of Ti-64 fixation in bone formation.




Figure 1 SEM micrograph and its EDS mapping on bone cross-section for Ti-64 fixation in defect area (a,d), opposite of defect (b,e), and far from the defect area (c,f).

Red arrow: Bone callus.




Figure 2 SEM micrograph and its EDS mapping on bone cross-section for control in defect area (a,d), opposite of defect (b,e), and far from the defect area (c,f). Yellow arrow: Incomplete bone formation, Red arrow: Bone callus

3.2 Bone properties evaluation

3.2.1 Vickers hardness test

Vickers hardness test was carried out to evaluate bone hardness and compared defect area to the part far from defect area. Results were plotted in bar chart (Fig. 3). From results, the hardness of bone callus is smaller than actual bone. Comparing only bone callus in both conditions, Ti-64 fixation resulted in higher hardness of bone callus than control. Moreover, hardness of bone callus on the area which far from the defect in control cannot be calculated due to insufficient space for indentation. From defect area and the area far from defect area in Ti-64 fixation, it can be said that the hardness of bone callus increases while in control, the hardness is almost the same in any parts excluding the area far from the defect area that is undefined. Other than that, actual bone shows almost similar bone hardness in either Ti-64 fixation or control.

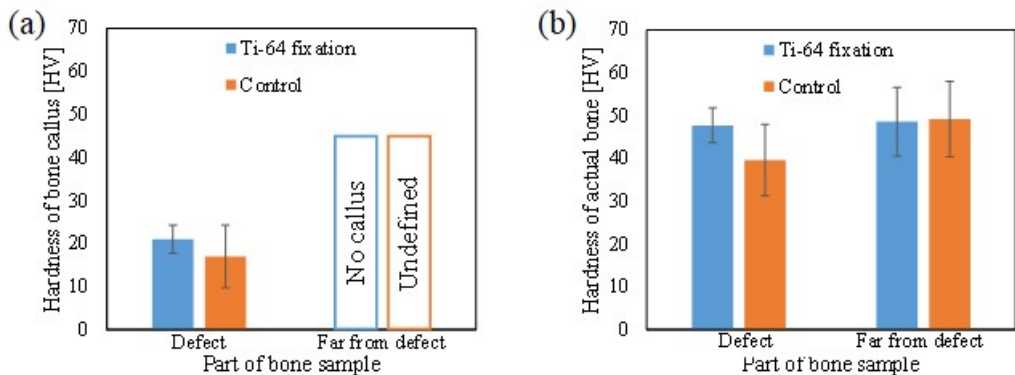


Figure 3 Vickers hardness of (a) bone callus, and (b) actual bone for Ti-64 fixation and control

3.2.2 X-ray diffraction analysis

Figure 4 shows the results of X-ray diffraction analysis of bone sample on defect side and opposite side for defect area and far from defect area. All the bone samples show similar peak for both Ti-64 fixation and control. However, defect area for control show weakest peak which only one clear peak was seen (Fig. 4c). This may be due to the incomplete bone formation. As generally known, X-ray diffraction can describe preferential orientation of apatite crystallites in calcified tissue [19,20]. Previous studies described the diffraction peaks of (002) and (310). It is being said that these two peaks are isolated from the other peaks and their normal plane is perpendicular to each other, thus the relative ratio of diffraction peak of (002) to the (310) could represent the preferential alignment of c-axis in apatite crystallites [19]. However, this study did not describe about the preferential alignment of c-axis but more to comparing the diffraction peak between bone callus and actual bone. Hence, this study proved that the diffraction peak is similar among all bone samples but only for control in defect area show the weakest diffraction peak due to incomplete bone formation.

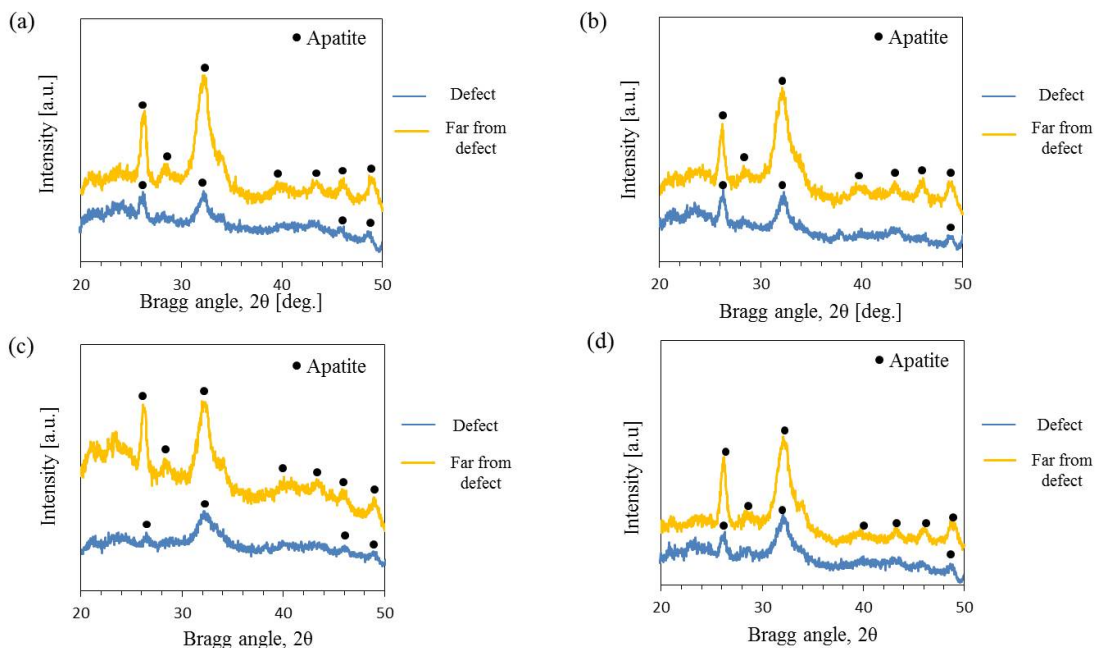


Figure 4 XRD profile of bone for Ti-64 fixation (a,b), and control (c,d).
a,c: defect side, b,d: opposite side

4. Conclusion

The study of bone healing after three weeks of healing period of an artificial defect made in rabbit femur are discussed in this study. Insertion of Ti-64 plate fixation resulted in rapid bone formation in the defect area even though external callus were still present in the area. This may be due to insufficient healing period which only during primary bone formation. Bone callus will be disappeared to form actual bone in secondary bone formation which needs about six weeks. In order to support this finding, the control was considered, which showed incomplete bone formation and more widespread formation of callus. Moreover, the hardness value of bone callus is much lower than actual bone. However, X-ray diffraction analysis show similar diffraction peak for all bone samples except for control where the bone formation is incomplete. Through this study, the importance of studying the surrounding of the bone defect is highlighted. In general cases, bone callus is expected to form solely on the defect area, but it is proved that the formation of bone callus on surrounding bone is more widespread than that expected from previous studies.

Acknowledgements

This work was supported in part by Grant-in-Aid for Scientific Research (C) (17K06071) from the Japan Society for the Promotion of Science (JSPS), Japan.

References

- [1] Cui FZ, Zhang Y, Wen HB, Zhu XD. Microstructural evolution in external callus of human long bone. *Mater. Sci. Eng.* 2000; C11: 27-33.
- [2] Schindeler A, McDonald MM, Bokko P, Little DG. Bone remodeling during fracture repair: The cellular picture. *Semin Cell Dev Biol.* 2008; 19: 459-66.
- [3] Slaets E, Carmeliet G, Naert I, Duyck J. Early cellular responses in cortical bone healing around unloaded titanium implants: An animal study. *J Periodontol.* 2006; 77: 1015-24.
- [4] Slaets E, Naert I, Duyck. Early cortical bone healing around loaded titanium implants: a histological study in the rabbit. *J. Clin Oral Impl Res.* 2009; 20: 126-34.
- [5] Gepreel MAH, Niinomi M. Biocompatibility of Ti-alloys for long-term implantation. *J Mech Behav Biomed Mater.* 2013; 20: 407-15.
- [6] Niinomi M. Mechanical properties of biomedical titanium alloys. *Mater Sci Eng.* 1998; A243: 231-6.
- [7] Hussein AH, Gepreel MAH, Gouda MK, Hefnawy AM, Kandil SH. Biocompatibility of new Ti-Nb-Ta base alloys. *Mater. Sci. Eng.* 2016; C61: 574-8.
- [8] Kopova I, Strasky J, Harcuba P, Landa M, Janecek M, Bacakova L. Newly developed Ti-Zr-Ta-Si-Fe biomedical beta titanium alloys with increased strength and enhanced biocompatibility. *Mater. Sci. Eng.* 2016; C60: 230-8.
- [9] Niinomi M, Liu Y, Nakai M, Liu H, Li H. Biomedical titanium alloys with Young's moduli close to that of cortical bone. *Regen Biomater.* 2016; 3(3): 173-85.
- [10] Niinomi M, M. Nakai. Titanium-based biomaterials for preventing stress shielding between implant devices and bone. *Int J Biomater.* 2011; ID 836587.
- [11] Sumitomo N, Noritake K, Hattori T, Morikawa K, Niwa S, Sato K, Niinomi M. Experiment study on fracture fixation with low rigidity titanium alloy. *J Mater Sci Mater Med.* 2008; 19: 1581-1586.
- [12] Slaets E, Carmeliet G, Naert I, Duyck J. Early trabecular bone healing around titanium implants: A histological study in rabbits. *J Periodontol.* 2007; 78: 510-8.
- [13] Isaksson H, Malkiewicz M, Nowak R, Helminen HJ, Jurvelin JS. Rabbit cortical bone tissue increases its elastic stiffness but becomes less viscoelastic with age. *Bone.* 2012; 47: 1030-8.
- [14] Lin DJ, Chuang CC, Lin JHC, Lee JW, Ju CP, Yin HS. Bone formation at the surfaces of low modulus Ti-7.5Mo implants in rabbit femur. *Biomater.* 2007; 28: 2582-9.
- [15] Yamaji T, Ando K, Wolf S, Augat P, Claes L. The effect of micromovement on callus formation. *J Orthop Sci.* 2001; 6: 571-5.
- [16] Claes L, Augat P, Sugar G, Wilke HJ. Influence of size and stability of the osteotomy gap on the success of fracture healing. *J Orthop Res.* 1997; 15: 577-84.
- [17] Uthoff HK, Bardos DI, Kiar ML. The advantages of titanium alloy over stainless steel plates for the internal fixation of fractures. *J Bone Jt Surg.* 1981; 63-B: 427-34.
- [18] Uthoff HK, Poitras P, Backman DS. Internal plate fixation of fractures: Short history and recent development. *J Orthop Sci.* 2006; 11: 118-26.
- [19] Nakano T, Kaibara K, Tabata Y, Nagata N, Enomoto S, Marukawa E, Umakoshi Y. Unique alignment and texture of biological apatite crystallites in typical calcified tissues analyzed by microbeam x-ray diffractometer system. *Bone.* 2002; 31: 479-87.
- [20] Ishimoto T, Nakano T, Umakoshi Y, Yamamoto M, Tabata Y. Degree of biological apatite c-axis orientation rather than bone mineral density controls mechanical function in bone regenerated using recombinant bone morphogenetic protein-2. *J. Bone Min. Res.* 2013; 28: 1170-9.